

PATIENT

Buddy Carter

PRESENTING CLINICAL SIGNS

History: Suspect PS. No further information provided.
 -Sedation: Torb.

SPECIES

Canine

ELECTROCARDIOGRAPHIC FINDINGS *Note: Single lead ECGs are evaluated as a rhythm strip. Morphology/MEA cannot be definitively commented on.

A single lead ECG is available; 50mm/s, 10mm/mV. The average heart rate is 100bpm (range 75-120bpm). The rhythm is sinus in origin, with a p for every QRS complex and vice versa. The P and QRS morphologies are positive. No ectopic beats, pauses or dysrhythmias observed. ECG diagnosis: Normal sinus rhythm with respiratory variation.

BREED

Chihuahua

SEX

Male Intact

ECHOCARDIOGRAM FINDINGS

2D, m-mode, color flow and doppler imaging is available. Continuous flow detected with color Doppler in the pulmonary artery in the region of the ductus arteriosus. The shunt appears primarily left to right, although extensive doppler evaluation is not performed. Moderate volume overload of the left heart with adequate systolic function. Increased LV sphericity. Moderate LA dilation. Trace central MR. No obvious TR. Normal pulmonic outflow velocities; no pulmonic insufficiency. MPA and branch dilation. The PV appears mildly thickened. Mildly elevated aortic outflow velocities with no AI. No pericardial or pleural effusion noted. No obvious cardiac masses.

AGE

5 years

CARDIAC CHART

WEIGHT

6.4lbs

INTERPRETED BY

Maggie Machen
 Lamy, DVM, DACVIM
 (Cardiology)

IMAGING PERFORMED BY

Sara Hansen

HOSPITAL NAME

The Ark Veterinary
 Clinic

REFERRING VET

Dr. Mercer

INVOICE

25223

DATE

7/8/22

CANINE CARDIAC PARAMETERS	MR VMAX (m/s)	TR VMAX (m/s)	LA/AO (Boon method)	LA/AO (Heart Base; Swe)	FS (%)	EF (%)	EPSS (cm)
NORMAL PARAMETER	4.5-5.5	<2.7	1.3	<1.6	28-40	40-100	<0.6
PATIENT	NA	NA	1.5	1.8	32	62	0.5
CANINE CARDIAC PARAMETERS	HR (BPM)	AV VMAX (m/s)	PV MAX (m/s)	BODY WEIGHT (kg)	LA 2D short axis Base view (cm)	LVIDd Avg: 2D and m-mode short axis (cm)	LVIDs Avg: 2D and m-mode short axis (cm)
NORMAL PARAMETER	50-100	0.7-1.7	0.7-1.6	BELOW	BELOW	BELOW	BELOW
PATIENT	80	2.3	1.1	2.9	1.8	3.1	2.1
*Normal chamber parameters expressed as a mean value (SD)				3	1.27 (5.3)	2.46 (2.46)	1.36 (5.5)
BODY WEIGHT DEPENDENT PARAMETERS				5	1.40 (4.5)	2.74 (5.2)	1.60 (4.7)
				10	1.50 (3.8)	3.27 (3.5)	2.06 (3.1)
				15	1.83 (2.0)	3.71 (2.4)	2.43 (2.1)
				20	2.02 (1.9)	4.14 (2.2)	2.80 (2.0)
				25	2.18 (2.4)	4.48 (2.9)	3.10 (2.5)
				30	2.33 (3.3)	4.83 (3.9)	3.39 (3.4)
				35	2.48 (4.3)	5.17 (5.0)	3.69 (4.5)
				40	2.62 (5.2)	5.48 (6.1)	3.96 (5.4)
				50	2.88 (7.1)	6.07 (8.3)	4.46 (7.4)

Adapted from June Boon, Veterinary Echocardiography, 1998
 Rishniw M and Hollis NE, J Vet Intern Med 2000; 14:429-435
 Hansson et al, Vet Rad and Ultrasound 2002
 Bonagura et al. Echocardiography: principles of interpretation, Vet Clin North Am 15:1177, 1995



PATIENT

Buddy Carter

SPECIES

Canine

BREED

Chihuahua

SEX

Male Intact

AGE

5 years

WEIGHT

6.4lbs

INTERPRETED BY

Maggie Machen
 Lamy, DVM, DACVIM
 (Cardiology)

IMAGING PERFORMED BY

Sara Hansen

HOSPITAL NAME

The Ark Veterinary
 Clinic

REFERRING VET

Dr. Mercer

INVOICE

25223

DATE

7/8/22

INTERPRETATION OF THE FINDINGS & FURTHER RECOMMENDATIONS

The cause of the murmur is a patent ductus arteriosus (PDA). This is a congenital condition where a blood vessel present in the fetus remains open after birth. When patent, this allows blood to recirculate through the lungs inappropriately and volume overloads the left heart chambers as is seen here. There is also trivial MR; however, this is clinically insignificant at this time. It is important to note that other small congenital defects can be easily missed in these cases, and advanced imaging with a Cardiologist is recommended. The ECG is unremarkable with a normal sinus rhythm.

Given moderate LA/LV dilation, this patient is at risk for progression to CHF, arrhythmias, PDA reversal due to development of pulmonary hypertension, exertional syncope, and/or sudden death at home in the future. Monitor sleeping respiratory rates at home to screen for progression to CHF.

Gold standard therapy is surgical closure of the vessel. This can be done interventionally or through a thoracotomy, and consultation with a local Cardiologist is recommended if sought (**highly recommended**). Success rates for the procedure are generally high, particularly given the asymptomatic status and a good chance for a normal life if closed appropriately. Regardless of whether or not surgery is elected, cardiac support with Pimobendan is recommended for long term benefit. If surgery is not an option, prognosis is guarded to poor long term and close monitoring is advised.

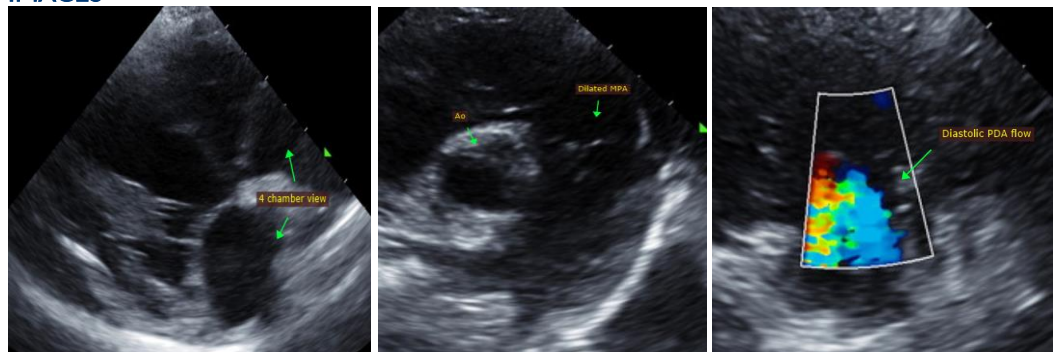
Omega fatty acid supplementation and mild salt restriction may be of some long-term benefit. Monitoring of sleeping breathing rates is recommended as the best way to screen for progression to CHF at home. Mild activity restriction is advised. Monitor at home for breathing changes, worsening cough, fainting episodes, exertional dyspnea.

PLAN

Institute Pimobendan 0.3mg/kg PO q12h. Recommend referral to a local Cardiologist for surgical consultation.

If not an option, reassess structure and function every 6 months lifelong to assess need for additional medications, sooner if clinical signs arise (progressive cough, labored breathing, syncope).

IMAGES





PATIENT

Buddy Carter

SPECIES

Canine

BREED

Chihuahua

SEX

Male Intact

AGE

5 years

WEIGHT

6.4lbs

INTERPRETED BY

Maggie Machen
Lamy, DVM, DACVIM
(Cardiology)

IMAGING PERFORMED BY

Sara Hansen

HOSPITAL NAME

The Ark Veterinary
Clinic

REFERRING VET

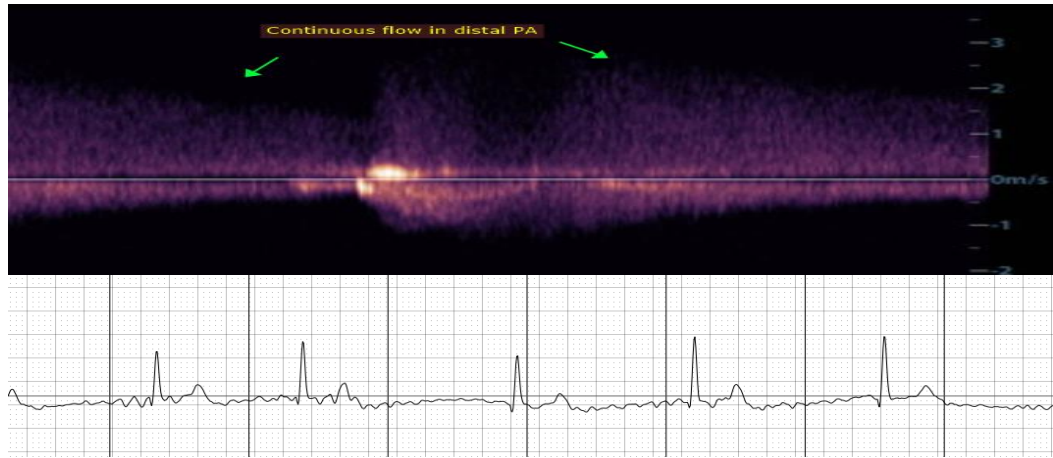
Dr. Mercer

INVOICE

25223

DATE

7/8/22



The information and recommendations provided are based on the images presented by the referring veterinarian. No evaluation can be communicated regarding pathology that was not visible in the image/video clips provided.

Thank you for this referral. This report was generated using transcription software, and minor dictation errors may be present. If the clinical or image interpretation does not parallel your findings or if I can be of any further assistance, please contact me.

Maggie Machen Lamy, DVM
Diplomate of the American College of Veterinary Internal Medicine (Cardiology)
info@sonopath.com